



Is the parietal lobe necessary for recollection in humans?

Jon S. Simons^{a,b,*}, Polly V. Peers^c, David Y. Hwang^{d,e,f}, Brandon A. Ally^{d,e,f},
Paul C. Fletcher^a, Andrew E. Budson^{d,e,f}

^a Brain Mapping Unit, University of Cambridge, Cambridge, UK

^b Behavioural and Clinical Neuroscience Institute, Department of Experimental Psychology, University of Cambridge, UK

^c MRC Cognition and Brain Sciences Unit, Cambridge, UK

^d Edith Nourse Rogers Memorial Veterans Hospital, Bedford, MA, USA

^e Brigham and Women's Hospital, Boston, MA, USA

^f Boston University Alzheimer's Disease Center, Boston, MA, USA

Received 13 June 2007; received in revised form 20 July 2007; accepted 28 July 2007

Abstract

An intriguing puzzle in cognitive neuroscience over recent years has been the common observation of parietal lobe activation in functional neuroimaging studies during the performance of human memory tasks. These findings have surprised scientists and clinicians because they challenge decades of established thinking that the parietal lobe does not support memory function. However, direct empirical investigation of whether circumscribed parietal lobe lesions might indeed be associated with human memory impairment has been lacking. Here we confirm using functional magnetic resonance imaging that significant parietal lobe activation is observed in healthy volunteers during a task assessing recollection of the context in which events previously occurred. However, patients with parietal lobe lesions that overlap closely with the regions activated in the healthy volunteers nevertheless exhibit normal performance on the same recollection task. Thus, although the processes subserved by the human parietal lobe appear to be recruited to support memory function, they are not a necessary requirement for accurate remembering to occur. © 2007 Elsevier Ltd. All rights reserved.

Keywords: Source memory; Recollection; fMRI; Neuroimaging; Parietal lobe; Lesion

1. Introduction

A number of recent reviews of the neuroimaging literature have noted the remarkable consistency with which parietal lobe activation has been associated with human memory (Cabeza & Nyberg, 2000; Rugg, Otten, & Henson, 2002; Wagner, Shannon, Kahn, & Buckner, 2005). Particularly evident has been the preponderance of activations observed during tasks in which participants recollect the context in which previous events occurred (Rugg et al., 2002; Wagner et al., 2005). Indeed, if one were to estimate the importance of a brain region for recollection on the basis solely of how often activation is reported in neuroimaging studies, the parietal lobe might, surprisingly, be assumed to be the most important region (Fig. 1). Such a conclusion would be surprising because it would challenge more than 50 years

of research establishing that frontal and medial-temporal lobe regions are the critical areas for memory (Aggleton & Brown, 1999; Fletcher & Henson, 2001; Simons & Spiers, 2003), whereas the parietal lobe supports spatial attention processes not obviously central to memory function (Critchley, 1953; Driver & Mattingley, 1998; Mesulam, 1999; Pardo, Fox, & Raichle, 1991). However, the consistent activation of the parietal lobe during memory tasks needs to be understood if full characterizations of memory are to be developed, as must related findings such as analysis of spontaneous correlations in brain activity suggesting the existence of a hippocampal-parietal memory network in humans and monkeys (Vincent et al., 2006, 2007).

One key unresolved issue concerns whether circumscribed parietal lobe lesions might be associated with impairment on the same tests of recollection that provoke neuroimaging activation (Wagner et al., 2005). It is well known that damage to medial parietal regions such as retrosplenial cortex and precuneus results in amnesia (Cavanna & Trimble, 2006; Valenstein et al., 1987), but little is known about the necessity of lateral parietal regions for accurate remembering. Here, we present a

* Corresponding author at: Department of Experimental Psychology, University of Cambridge, Downing Street, Cambridge CB2 3EB, UK.

E-mail address: jss30@cam.ac.uk (J.S. Simons).

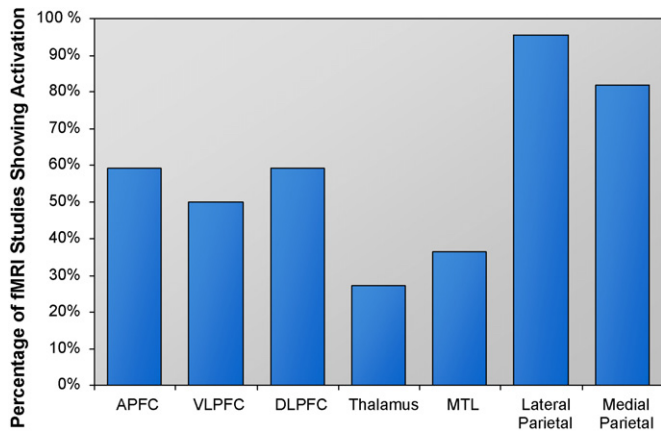


Fig. 1. Histogram illustrating the consistency with which different brain regions were activated in previous neuroimaging studies of recollection. Results included in the meta-analysis contrasted correct source attributions or “remember” responses, considered to require recollection of the context in which events occurred, against correct item recognition, “know” responses, or other non-recollective baseline conditions. A number of regions generally considered to play an important role in memory, such as anterior (APFC), ventrolateral (VLPFC) and dorsolateral (DLPFC) prefrontal cortex, thalamus, and the medial-temporal lobe (MTL), were in fact only observed in around half the neuroimaging studies to report whole-brain results. By contrast, lateral and, to a lesser extent, medial regions of the parietal lobe are activated in the vast majority of recollection experiments.

combined functional magnetic resonance imaging (fMRI) and patient investigation of this issue, using a test of recollection which we first confirmed to elicit parietal lobe activation in healthy volunteers, before determining the test’s susceptibility to parietal lobe lesions which overlapped closely with the regions activated in the healthy volunteers. Given the critical role that the lateral parietal lobe is known to play in spatial attention (Driver & Mattingley, 1998; Mesulam, 1999; Pardo et al., 1991), a non-spatial memory task was chosen for the present investigation so that our findings would not be confounded by spatial impairments that might follow parietal lobe lesions. In addition, we examined whether parietal lobe involvement in recollection was modulated by the use of different stimulus classes, such as words and faces (Kelley et al., 1998; Polyn, Natu, Cohen, & Norman, 2005).

As illustrated in Fig. 2, participants first undertook a study phase, in which they encountered words and famous faces and, for each stimulus, were cued to make either a semantic judgment (“does the stimulus relate more to entertainment or to politics?”) or a pleasantness judgment (“does the stimulus seem pleasant or unpleasant to you?”). The following test phase examined participants’ ability to remember which of the two judgments they had previously undertaken with each stimulus: entertainment/politics or pleasant/unpleasant (Simons, Gilbert, Owen, Fletcher, & Burgess, 2005; Simons, Owen, Fletcher, & Burgess, 2005). Such a task is considered a test of source recollection because success requires retrieval of the context (the cognitive operations that were engaged during the encoding task, as well as other associated details) in which the stimulus was previously encountered (Johnson, Hashtroudi, & Lindsay, 1993). If, as the persistent neuroimaging findings might suggest, the parietal lobe is critically important for recollection, then significant impair-

ments on our task would be predicted in patients whose lesions overlap with the areas activated in healthy volunteers. If, however, the established thinking is correct that the parietal lobe is not central for recollection, we would predict that no significant impairments on our task would emerge.

2. Methods

2.1. Participants

Thirty-two right-handed native speakers of English (20 female; mean age = 22.9 years, range 18–29), with normal or corrected-to-normal vision, took part in the two fMRI experiments (16 in each experiment). In addition, six patients with stable, non-traumatic unilateral parietal lobe lesions took part in the behavioral experiment, along with six healthy control volunteers, matched individually with the patients on the basis of age and premorbid intelligence (see Table 1). Patients were recruited without regard for behavioral profile, on the basis of their lesion record indicating stable, non-traumatic unilateral brain injury affecting one of the areas of lateral parietal cortex that had exhibited significant activation in the fMRI study (see Supplementary Fig. 1 for etiologies and individual patient lesions, and Fig. 3b for overlap between the patients’ lesions and the areas of fMRI activation identified in the healthy volunteers). Informed consent was obtained from all participants in a manner approved by the Brigham and Women’s Hospital, Addenbrooke’s NHS Trust, and Cambridge Psychology Research Ethics Committees.

2.2. Procedure

2.2.1. fMRI experiments

In both fMRI experiments, the stimuli consisted of words and grayscale photographs of famous faces (120 of each in the first experiment and 80 of each in the second). Forty percent of each class of stimuli related to entertainment and 40% to politics, and were used as target stimuli in the study and test phases of the memory task. The remaining stimuli, which related to fields other than entertainment or politics, were used as baseline items in the test phases.

In the study phases (see Fig. 2), participants encountered words and famous faces presented singly and, for each stimulus, were cued to make either a semantic judgment (“does the stimulus relate more to entertainment or to politics?”) or a pleasantness judgment (“does the stimulus seem pleasant or unpleasant to you?”). Additional orthogonal manipulations varied, in the first experiment, the side of the screen on which the stimuli were presented and, in the second experiment, which of two temporally-distinct lists stimuli appeared in. In the test phases, participants were presented with previously encountered target stimuli and, for half the stimuli, were cued to recollect which of the two judgments they had previously undertaken with each stimulus: entertainment/politics or pleasant/unpleasant. For the remaining target stimuli, participants were cued to recollect which side of the screen (first experiment) or which temporally-distinct list (second experiment) stimuli had been presented in. In addition, non-studied baseline words and famous faces were presented and participants were cued to make living/non-living judgments about the words or male/female judgments about the faces. Behavioral responses were made using a button box. The present analysis concentrates on brain activity consistently observed across the test phases of both fMRI experiments associated with the contrast between recollection of the study phase judgment that had been undertaken on target stimuli and the baseline condition, separately for words and faces. Brain regions associated with common activation across stimulus classes during the other conditions mentioned are discussed elsewhere (Simons, Gilbert et al., 2005; Simons, Owen et al., 2005).

2.2.2. Patient experiment

In the patient experiment, the study phase consisted of 40 words and 40 famous faces which were presented singly in the center of the monitor screen, and participants were cued to make the same semantic or pleasantness judgments as in the fMRI experiments. In the subsequent test phase, studied and non-studied stimuli were presented and participants recollected which of the two judgments




Fig. 2. Examples of the stimuli used during the recollection task. In the study phase, participants encountered words or famous faces and were cued to make either a semantic judgment (“does the stimulus relate more to entertainment or to politics?”) or a pleasantness judgment (“does the stimulus seem pleasant or unpleasant to you?”) about them. In the test phase, participants were asked to remember which of the two judgments they had previously undertaken with each stimulus: entertainment/politics or pleasant/unpleasant.

Table 1
 Performance of the patients with parietal lobe lesions and matched control participants on a range of neuropsychological tests (see text for references)

Tests	Parietal patients						Controls	
	L1	L2	L3	R1	R2	R3	M	S.D.
Mini-mental state exam (30)	30	30	28	30	30	29	29.17	0.98
Line bisection error (mm) ^a	-6.5*	2.5	2.8	-1.3	2	-0.5	-0.26	2.97
Target cancellation (misses/60)	0	1	7*	0	0	0	1.00	1.26
Spatial bias ^b	0.84*	0.46	0.68*	0.48	0.45	0.36*	0.49	0.06
NART premorbid IQ (50)	29*	47	41	42	43	34	42.50	5.05
Boston naming test (60)	52*	59	59	60	60	60	59.20	1.79
Letter fluency	35	52	44	51	49	36	52.83	9.52
Trail making test—B (sec)	116*	70	103*	76	40	80	60.00	20.98
Rey figure copy (36)	29.5	35	36	36	34	33.5	35.60	0.89
Rey figure delayed recall (36)	21.5	24	19.5	22	20.5	13	19.90	6.21
Digit span score (30)	13*	24	12*	22	19	12*	22.40	3.36

L: left parietal lesion; R: right parietal lesion.

^a Mean error from true midpoint in three bisections of lines 205 mm in length (-ve left, +ve right).

^b Scores <0.5 = bias to right; scores >0.5 = bias to left.

* Significant impairment compared with controls.

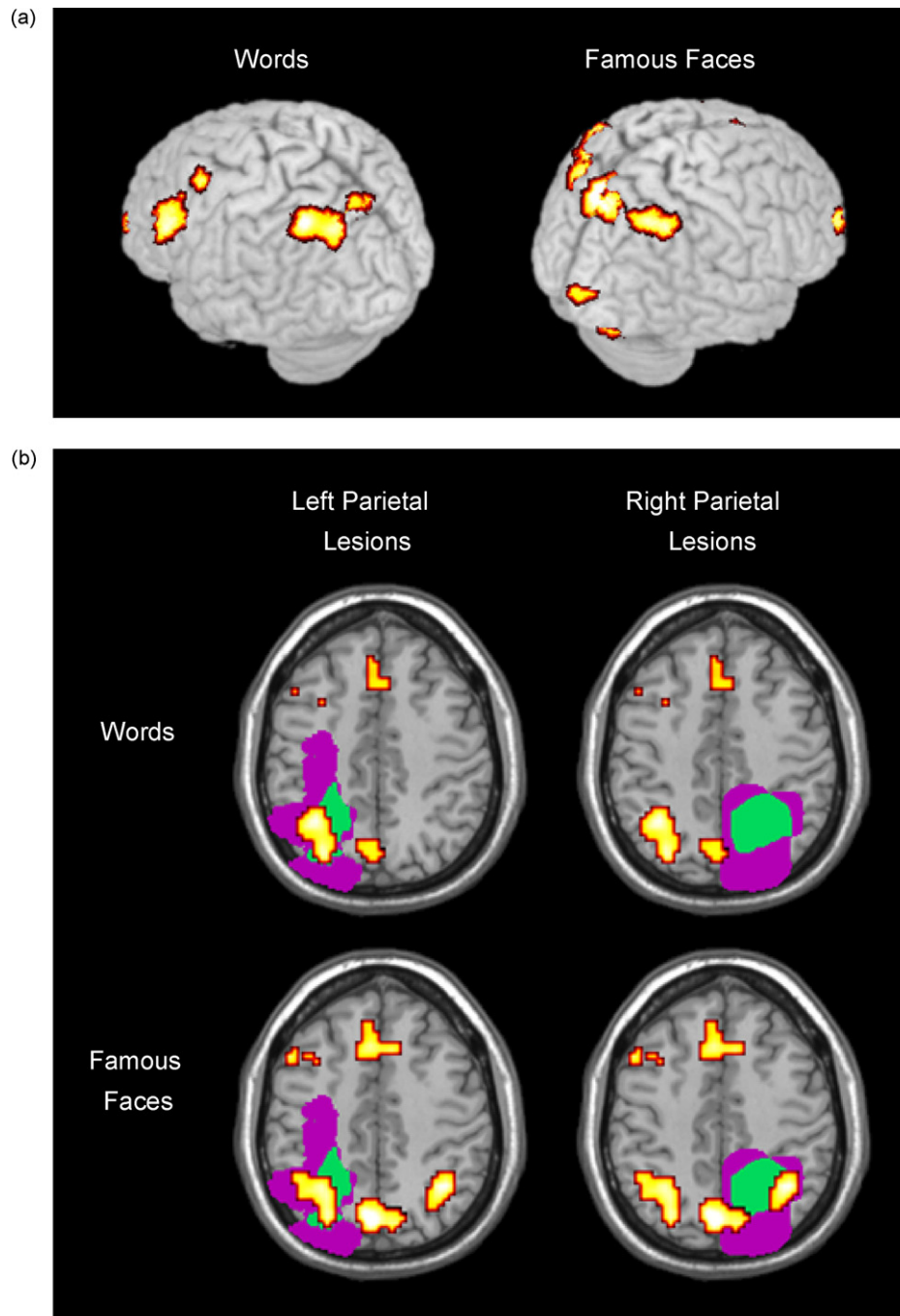


Fig. 3. Close overlap between the parietal lobe regions activated in healthy volunteers during source recollection and the regions damaged in the patients with parietal lobe lesions. (a) Brain regions consistently associated with source recollection across two separate fMRI experiments involving healthy volunteers included left lateral parietal cortex for words and bilateral lateral parietal cortex for famous faces, among other areas. Figure shows activation that was significantly greater for source recollection than for a baseline condition, displayed on a 3D canonical brain. (b) Lesion overlay diagrams illustrating the close correspondence between the location of the patients' parietal lobe lesions and the areas of fMRI activation identified in the healthy volunteers.

(entertainment/politics or pleasant/unpleasant) they had made about the stimuli that they considered to have been previously encountered. Participants were given as much time as they needed to respond in the test phase; in fact, the patients and healthy control participants did not differ in their response times, $t(10) = 0.77$; $P = 0.46$.

2.2.3. Neuropsychological assessment

Patients and healthy controls were also administered a battery of neuropsychological tests that included measures of visual neglect (line bisection: Wilson,

Cockburn, & Halligan, 1987; target cancellation: Weintraub & Mesulam, 1985), visuospatial bias (Peers et al., 2005), premorbid intelligence (NART: Nelson & Willison, 1991), semantic processing (Boston naming test: Kaplan, Goodglass, & Weintraub, 1983), and executive functions (Trail making test: Tombaugh, 2004) (see Table 1). As the patients were at least 6 months post-insult, they did not exhibit profound visual attentional impairments such as florid neglect, which can accompany acute parietal lobe injury. However, evidence of changes in spatial bias (Peers et al., 2005) remained, with two of the patients with left parietal lesions exhibiting a significant tendency to attend preferentially to the left side of space. A similar attentional bias to the ipsilesional side of space was also

apparent in each of the patients with right-sided lesions, reaching significance in one case.

2.3. Imaging acquisition and data analysis

A 3T Bruker system was used in both fMRI experiments to acquire echo-planar functional images (TR = 1100 ms, TE = 27.5 ms, 21 interleaved axial slices oriented $\sim 10^\circ$ from the AC–PC transverse plane, 4 mm thickness, 1 mm inter-slice skip). Data were preprocessed and analyzed using SPM2 (Wellcome Department of Imaging Neuroscience, London). Images were corrected for differences in slice acquisition time and effects of motion, before undergoing an undistortion procedure using magnetic field maps (Cusack, Brett, & Osswald, 2003) and being normalized to an EPI template in MNI stereotactic space. Normalized images were re-sampled into 3 mm cubic voxels and then spatially smoothed with an 8 mm FWHM isotropic Gaussian kernel. Random effects statistical analysis was undertaken using conjunction contrasts to identify brain regions consistently activated across the two fMRI experiments, using non-sphericity correction (Friston et al., 2002). Activations were reported if they exceeded the threshold of $P < 0.001$ corrected for multiple comparisons across the entire brain and consisted of at least 10 contiguous voxels. Patients' lesions were traced from structural MRI scans or lesion diagrams and overlaid with the areas of fMRI activation from the healthy volunteers using MRICro software (Rorden & Brett, 2000).

3. Results

3.1. Parietal lobe activation during source recollection

The analysis focuses initially on the brain regions showing consistent activation across the test phases of two separate fMRI experiments involving healthy volunteers (Fig. 3a). Correctly recollecting the study phase judgment previously undertaken with word stimuli (mean accuracy = 0.72, standard deviation = 0.17), versus baseline, was associated with significantly above-threshold activation in left lateral parietal cortex (Brodmann's area (BA) 40/7). Recollection involving face stimuli (mean accuracy = 0.73, standard deviation = 0.17) led to significant activation in brain regions that included both left and right lateral parietal cortex (also BA 40/7). Looking at each parietal region individually, there was no difference in activation between stimulus classes in left lateral parietal cortex, $t(31) = 0.02$; $P = 0.99$, but right lateral parietal cortex was significantly more involved during recollection of faces than words, $t(31) = 2.41$; $P < 0.05$. Analysis of data from one of the fMRI experiments, in which there was sufficient power to permit comparison of successful and unsuccessful recollection, revealed that activation in both parietal cortices was sensitive to recollection accuracy, $F(1, 15) > 7.5$; $P < 0.015$. Outside lateral parietal cortex, significant recollection-related activation was observed for words and faces consistently across both experiments in anterior (BA 10), ventrolateral (BA 47/45) and dorsolateral (BA 9) regions of prefrontal cortex, as well as in precuneus (BA 7). Roles played by these other regions have been discussed elsewhere (Simons, Gilbert et al., 2005; Simons, Owen et al., 2005), and we do not consider them further here.

3.2. Source recollection following parietal lobe lesions

As noted in Section 2, patients were recruited on the basis of their lesion record indicating stable, non-traumatic unilat-

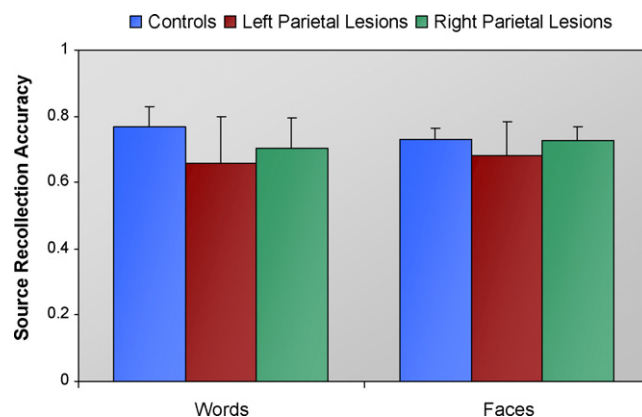


Fig. 4. Performance of the patients with left and right parietal lobe lesions and matched control participants on the memory task assessing source recollection involving words and famous faces. Error bars indicate standard error of the mean.

eral brain injury affecting one of the areas of lateral parietal cortex that had exhibited significant activation across the fMRI experiments. Fig. 3b illustrates the substantial overlap between the patients' lesions and the areas of fMRI activation identified in the healthy volunteers. The key question is whether the patients with parietal lobe lesions would exhibit significant impairment on our source recollection task. Despite the close overlap between the lesions and the areas of fMRI activation, no significant impairments were observed in recollecting which of the study phase judgments was made about previously encountered stimuli (Fig. 4). Using non-parametric Mann–Whitney tests, the patients with parietal lobe lesions were unimpaired in recollection involving words, $U = 14.5$; $P = 0.59$, or faces, $U = 16.0$; $P = 0.82$. Even using more powerful, but less robust, parametric t -tests, no significant differences emerged between the parietal lobe patients and controls in recollection involving words, $t(10) = 0.94$; $P = 0.38$, or faces, $t(10) = 0.39$; $P = 0.71$.

Non-significant group differences might always potentially be attributable to insufficient power. To assess the reliability of these group results across individual patients, therefore, we calculated for each patient whether his/her source recollection scores were greater than two standard deviations below the scores of the patient's matched control participant. Using this measure, one of the patients with left parietal damage (patient L1) exhibited significant impairment in recollection involving famous faces, but not words. This patient was among those who exhibited a significant spatial bias, tending to attend preferentially to the left side of space (see Section 2). However, this attentional bias is unlikely to be an explanation for his poor performance on the faces recollection task as he was 100% correct on the semantic judgment made using identical stimuli during the study phase, suggesting he had little difficulty perceiving the stimuli. Poor performance of this patient on a number of the neuropsychological tasks administered (see Table 1) indicated generalized difficulty in a range of cognitive domains, to which his reduced recollection of faces may be attributable. In fact, examination of patient L1's structural scan (see Supplementary Fig. 1) suggests that there may be some extension of his lesion into the frontal lobes, damage to which is known to cause consid-

erable recollection impairment (Duarte, Ranganath, & Knight, 2005; Simons et al., 2002).

Critically, all the remaining patients, whose lesions did not encroach into the frontal lobes, performed normally at recollecting both words and faces. Furthermore, there was no evidence for stimulus class differences in source recollection when contrasting the patients with left and right parietal lesions as a whole (potentially analogous to the effect observed in the fMRI data). When recollection of words and faces was examined separately for each group of patients, no differences in recollection between stimulus classes emerged either for patients with left parietal lobe lesions, Wilcoxon $Z=0$; $P=0.99$, or right parietal lobe lesions, $Z=0.27$; $P=0.79$. Again, this result was replicated using parametric t -tests, $t_{\max}=0.45$, $P_{\min}=0.70$.

4. Discussion

Overall, the data from this study demonstrate that parietal lobe lesions which overlap closely with the regions activated in healthy volunteers during source recollection are not associated with significantly impaired performance on the same source recollection task. This study is, as far as we are aware, the first direct empirical investigation to focus on the effects of parietal lobe lesions on memory function in humans, despite many years of research into the role the region plays in other cognitive abilities, such as visual attention. Our findings correspond with the impression of many clinicians and neuropsychologists that patients with lateral parietal lobe damage do not typically suffer from an amnesic syndrome (Critchley, 1953; Driver & Mattingley, 1998; Mesulam, 1999; Pardo et al., 1991), and are consistent with reports of patients with posterior cortical atrophy, who exhibit neuronal degeneration affecting parietal regions, but in whom memory is often relatively preserved until late in the progression of the disease (Benson, Davis, & Snyder, 1988).

The present results are also consistent with a recent investigation by Rossi et al. (2006) of the effects of transient disruption of parietal lobe activity following transcranial magnetic stimulation (TMS). Rossi et al. reported “negligible” effects on recognition memory performance of TMS to similar areas of parietal cortex as were lesioned in the patients described here. Despite the lack of an impact on recognition memory, TMS to these parietal regions did disrupt performance on a visual attention task (Rossi et al., 2006), consistent with the findings in the present experiment and in the previous literature. Although recognition memory is generally considered to depend on contributions from recollection and familiarity (Mandler, 1980; Yonelinas, 2002), Rossi et al. did not examine whether parietal lobe TMS affected performance of a source recollection task specifically. The present data would predict little detrimental effect on such a task of TMS targeting the same regions of parietal cortex as were activated in the present fMRI experiments. However, further studies are required to address this issue conclusively.

If, as the data from the present experiment suggest, parietal lobe dysfunction does not result in recollection impairment, an important question is why the parietal lobe so consistently exhibits functional activation during neuroimaging studies of

recollection (Fig. 1). One obvious possible explanation could be that the recollection task employed in the present experiment may not have been sensitive enough to reveal a memory deficit that might be present in the patients with parietal lobe lesions. While this is always a possible explanation in experiments that report non-significant differences between patients and controls, we took considerable care when piloting to ensure that control participants would be below ceiling levels of performance (their mean recollection score was in fact 0.75), maximizing the possibility that a significant deficit would emerge if it did exist. Furthermore, it is worth noting that the patients were also unimpaired at delayed recall of the Rey figure (see Table 1). However, future studies that adopt other measures of memory function (evaluating, for example, confidence or richness of recollection) are needed to ensure that our results are not due solely to the tasks we used. Another possible explanation is that only patients with unilateral parietal lobe lesions were included in the present study, and that bilateral lesions might be required for memory dysfunction to be observed. It is very unusual for patients to present with selective bilateral parietal lobe lesions that do not also implicate many other brain regions. However, the bilateral parietal neurodegeneration associated with posterior cortical atrophy generally results in fewer memory difficulties than are usually reported in typical Alzheimer’s disease (Benson et al., 1988).

Alternatively, it may be that although processes supported by the lateral parietal lobe can contribute to memory function, these processes are not critical to recollection success. For example, if the parietal lobe subserves visuospatial attention processes as is commonly supposed, perhaps healthy individuals recruit these processes to orient attention towards particular aspects of internally-represented mnemonic information when performing a recollection task (Rugg & Wilding, 2000; Wagner et al., 2005). One possibility is that, following a parietal lobe lesion, functional reorganization might occur such that neighboring intact brain tissue takes on the processes of attending to mnemonic representations. However, there is little evidence for such rapid reorganization of memory functions in the literature. Alternatively, patients with parietal lobe lesions may develop a different strategy when recollecting contextual details that relies on processes subserved by other brain regions known also to be involved in memory function, such as the frontal and medial-temporal lobes (Fletcher & Henson, 2001; Simons & Spiers, 2003). Evidence for possible differential utilization of brain regions within this putative fronto-parieto-medial-temporal memory network (Fletcher & Henson, 2001; Simons & Spiers, 2003; Vincent et al., 2006, 2007) will require the study of patients with parietal lesions who are performing memory tasks while being scanned using fMRI. Such studies, perhaps including analysis of connectivity between regions in the putative network, will allow determination of whether patients with parietal lobe lesions are able to show accurate recollection by drawing on functional parietal tissue that may remain, or whether they are recruiting other compensatory brain regions to support their ability to remember past events.

To conclude, in the present study we found that patients with circumscribed brain lesions that overlapped closely with

the parietal lobe regions activated in an fMRI study of source recollection involving healthy volunteers nevertheless exhibited normal source recollection performance. Despite parietal cortex activation being reported in numerous fMRI experiments of memory, therefore, the currently available lesion and TMS evidence suggests that the lateral parietal cortex is not necessary for accurate remembering to occur. Replication and extension of these findings is required before the necessity of parietal cortex for memory can be fully understood. However, one consequence of the current evidence is that investigators may choose to adopt caution in seeking to generate elaborate theories detailing the critical role that the parietal lobe might play in memory. Whatever role is played by this region may not be critical, and might perhaps turn out to be better understood as some kind of supplementary, strategy-dependent function that can contribute to the mnemonic operations subserved by other, more necessary regions in the distributed cortical memory network.

Acknowledgements

We are grateful to Peter Black and Kirk Daffner for allowing us to approach patients under their care. This work was supported by the Wellcome Trust and by National Institute on Aging grants R01 AG025815 and P30 AG13846.

Appendix A. Supplementary data

Supplementary data associated with this article can be found, in the online version, at doi:10.1016/j.neuropsychologia.2007.07.024

References

Aggleton, J. P., & Brown, M. W. (1999). Episodic memory, amnesia, and the hippocampal-anterior thalamic axis. *Behavioral and Brain Sciences*, *22*, 425–489.

Benson, D. F., Davis, R. J., & Snyder, B. D. (1988). Posterior cortical atrophy. *Archives of Neurology*, *45*, 789–793.

Cabeza, R., & Nyberg, L. (2000). Imaging cognition II: An empirical review of 275 PET and fMRI studies. *Journal of Cognitive Neuroscience*, *12*, 1–47.

Cavanna, A. E., & Trimble, M. R. (2006). The precuneus: A review of its functional anatomy and behavioural correlates. *Brain*, *129*, 564–583.

Critchley, M. (1953). *The parietal lobes*. New York: Hafner.

Cusack, R., Brett, M., & Osswald, K. (2003). An evaluation of the use of magnetic field maps to undistort echo-planar images. *NeuroImage*, *18*, 127–142.

Driver, J., & Mattingley, J. B. (1998). Parietal neglect and visual awareness. *Nature Neuroscience*, *1*, 17–22.

Duarte, A., Ranganath, C., & Knight, R. T. (2005). Effects of unilateral prefrontal lesions on familiarity, recollection, and source memory. *Journal of Neuroscience*, *25*, 8333–8337.

Fletcher, P. C., & Henson, R. N. A. (2001). Frontal lobes and human memory: Insights from functional neuroimaging. *Brain*, *124*, 849–881.

Friston, K. J., Glaser, D. E., Henson, R. N. A., Kiebel, S., Phillips, C., & Ashburner, J. (2002). Classical and Bayesian inference in neuroimaging: Applications. *NeuroImage*, *16*, 484–512.

Johnson, M. K., Hashtroudi, S., & Lindsay, D. S. (1993). Source monitoring. *Psychological Bulletin*, *114*, 3–28.

Kaplan, E. F., Goodglass, H., & Weintraub, S. (1983). *The Boston naming test*. Philadelphia: Febiger.

Kelley, W. M., Miezin, F. M., McDermott, K. B., Buckner, R. L., Raichle, M. E., Cohen, N. J., et al. (1998). Hemispheric specialization in human dorsal frontal cortex and medial temporal lobe for verbal and nonverbal memory encoding. *Neuron*, *20*, 927–936.

Mandler, G. (1980). Recognizing: The judgment of previous occurrence. *Psychological Review*, *87*, 252–271.

Mesulam, M. M. (1999). Spatial attention and neglect: Parietal, frontal and cingulate contributions to the mental representation and attentional targeting of salient extrapersonal events. *Philosophical Transactions of the Royal Society of London Series B: Biological Sciences*, *354*, 1325–1346.

Nelson, H. E., & Willison, J. (1991). *National adult reading test revised: test manual*. Windsor: NFER-Nelson.

Pardo, J. V., Fox, P. T., & Raichle, M. E. (1991). Localization of a human system for sustained attention by positron emission tomography. *Nature*, *349*, 61–64.

Peers, P. V., Ludwig, C. J. H., Rorden, C., Cusack, R., Bonfiglioli, C., Bundesen, C., et al. (2005). Attentional functions of parietal and frontal cortex. *Cerebral Cortex*, *15*, 1469–1484.

Polyn, S. M., Natu, V. S., Cohen, J. D., & Norman, K. A. (2005). Category-specific cortical activity precedes retrieval during memory search. *Science*, *310*, 1963–1966.

Rorden, C., & Brett, M. (2000). Stereotaxic display of brain lesions. *Behavioural Neurology*, *12*, 191–200.

Rossi, S., Pascualetti, P., Zito, G., Vecchio, F., Cappa, S. F., Miniussi, C., et al. (2006). Prefrontal and parietal cortex in human episodic memory: An interference study by repetitive transcranial magnetic stimulation. *European Journal of Neuroscience*, *23*, 793–800.

Rugg, M. D., Otten, L. J., & Henson, R. N. A. (2002). The neural basis of episodic memory: Evidence from functional neuroimaging. *Philosophical Transactions of the Royal Society of London Series B: Biological Sciences*, *357*, 1097–1110.

Rugg, M. D., & Wilding, E. L. (2000). Retrieval processing and episodic memory. *Trends in Cognitive Sciences*, *4*, 108–115.

Simons, J. S., Gilbert, S. J., Owen, A. M., Fletcher, P. C., & Burgess, P. W. (2005). Distinct roles for lateral and medial anterior prefrontal cortex in contextual recollection. *Journal of Neurophysiology*, *94*, 813–820.

Simons, J. S., Owen, A. M., Fletcher, P. C., & Burgess, P. W. (2005). Anterior prefrontal cortex and the recollection of contextual information. *Neuropsychologia*, *43*, 1774–1783.

Simons, J. S., & Spiers, H. J. (2003). Prefrontal and medial temporal lobe interactions in long-term memory. *Nature Reviews Neuroscience*, *4*, 637–648.

Simons, J. S., Verfaellie, M., Galton, C. J., Miller, B. L., Hodges, J. R., & Graham, K. S. (2002). Recollection-based memory in frontotemporal dementia: Implications for theories of long-term memory. *Brain*, *125*, 2523–2536.

Tombaugh, T. N. (2004). Trail Making Test A and B: Normative data stratified by age and education. *Archives of Clinical Neuropsychology*, *19*, 203–214.

Valenstein, E., Bowers, D., Verfaellie, M., Heilman, K. M., Day, A., & Watson, R. T. (1987). Retrosplenial amnesia. *Brain*, *110*, 1631–1646.

Vincent, J. L., Patel, G. H., Fox, M. D., Snyder, A. Z., Baker, J. T., Van Essen, D. C., et al. (2007). Intrinsic functional architecture in the anaesthetized monkey brain. *Nature*, *447*, 83–86.

Vincent, J. L., Snyder, A. Z., Fox, M. D., Shannon, B. J., Andrews, J. R., Raichle, M. E., et al. (2006). Coherent spontaneous activity identifies a hippocampal-parietal memory network. *Journal of Neurophysiology*, *96*, 3517–3531.

Wagner, A. D., Shannon, B. J., Kahn, I., & Buckner, R. L. (2005). Parietal lobe contributions to episodic memory retrieval. *Trends in Cognitive Sciences*, *9*, 445–453.

Weintraub, S., & Mesulam, M. M. (1985). Mental state assessment of young and elderly adults in behavioral neurology. In M. M. Mesulam (Ed.), *Principles of behavioral neurology* (pp. 71–123). Philadelphia, PA: Davis FA.

Wilson, B. A., Cockburn, J., & Halligan, P. W. (1987). *Behavioural inattention test*. Fareham, UK: Thames Valley Test Company.

Yonelinas, A. P. (2002). The nature of recollection and familiarity: A review of 30 years of research. *Journal of Memory and Language*, *46*, 441–517.